

## REVIEW ARTICLE

# Multimodality Image Fusion for Coronary Artery Disease Detection: Concepts and Latest Developments

Marina Piccinelli, PhD, David C. Cooke, MSEE and Ernest V. Garcia, PhD

Received: May 2, 2018/Revised manuscript received: June 26, 2018/Accepted: June 29, 2018

© The Japanese Society of Nuclear Cardiology 2018

## Abstract

**The debate on the role of anatomy and function in the assessment of coronary artery disease has been progressing for decades. While each imaging modality brings its own strengths and weaknesses, a multimodality image fusion approach combining an anatomical acquisition with a functional one has the potential of providing all the complementary information necessary to select the proper treatment. The technology has been available to physicians for a decade, but the recent introduction of positron emission tomography-derived absolute myocardial blood flow has further advanced the case for an image fusion diagnostic approach.**

**Keywords:** CAD, MPI, Multimodality image fusion

**Ann Nucl Cardiol 2018; 4 (1): 74–78**

**D**espite the significant improvements achieved in the last decades, coronary artery disease (CAD) remains one of the leading causes of death in the United States. The recently published annual report (1) from the American Heart Association estimated that more than 130 million adults of the US population will have some form of cardiovascular disease by 2035 with healthcare costs expected to reach \$1.1 trillion. Accordingly, the field of cardiovascular imaging has experienced a continuous growth determined by the constant technological enhancements of imaging devices and fostered by the clinical need of more sophisticated and reliable diagnostic techniques. In fact, a large proportion of patients (roughly 2/3) scheduled for elective invasive coronary angiography (ICA) do not ultimately exhibit obstructive disease (2, 3). While ICA may remain the gold standard for CAD assessment, its invasive nature greatly limits its application to broad populations and strengthen the need for efficient noninvasive techniques.

The most common noninvasive techniques for CAD diagnosis can be divided in anatomical-primarily coronary computed tomography (CTA) and magnetic resonance (MR)- and *functional*-single-photon emission computed tomography (SPECT), positron emission tomography (PET) and MR-

depending on whether they allow a precise evaluation of the morphology of coronary and myocardium or they assess the presence and extent of myocardial ischemia (4). This classification ultimately embodies the scientific debate that has been conducted over the last decades aimed at identifying which aspects of CAD are decisive in assessing disease severity and should be the focus of treatment (5). While traditionally only morphological considerations were used, the development of fractional flow reserve (FFR) (6) and results from pivotal clinical trials (7) have shown the importance of considering the functional significance of a lesion before any decision on treatment can be made, originating a new paradigm shift in approaches and assumptions.

## Multimodality image fusion

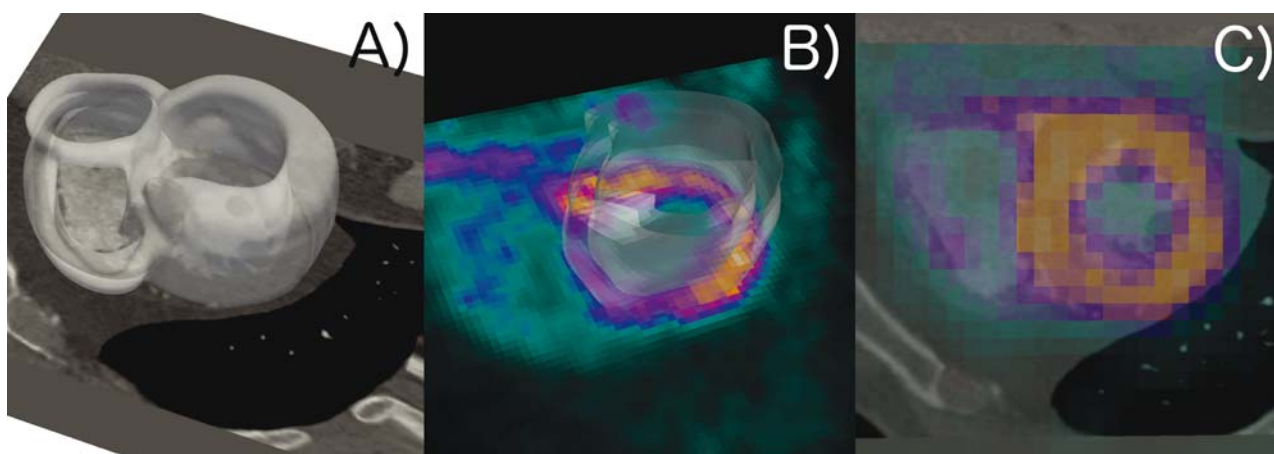
While the discussion on anatomy versus function as key players in guiding patients' management remains crucial in clinical practice, it has also motivated the introduction of a diagnostic strategy that integrates into a single display anatomical/functional information independently extracted from separate acquisitions and yields a comprehensive description of disease. Since each imaging technique possesses unique strengths and weaknesses, *multimodality*

doi: 10.17996/anc.18-00065

Marina Piccinelli, C David Cooke, Ernest V Garcia

Department of Radiology and Imaging Science, Emory University  
School of Medicine, 1364 Clifton Rd, NE, Atlanta, Georgia, 30322,  
United States

E-mail: mpiccin@emory.edu



**Fig. 1** A) LV myocardium retrieval from CTA, B) LV myocardium retrieval from PET, C) fused image display.

*image fusion (MIF)* provides complementary diagnostic and prognostic information and enhances physicians' ability to select the appropriate treatment (8). The use of multiple image acquisitions to diagnose is not unusual for clinicians, especially if the first diagnostic test is inconclusive. Physicians have learned to *mentally fuse* the information contributed by each dataset and provide a global assessment. In a study conducted by Santana et al. (9), the authors specifically investigated the added diagnostic value provided by fused SPECT/CTA display in CAD evaluation compared to the side-by-side reading. They showed that in 28% of the cases the physicians modified their decision when provided with software-integrated images. The availability of fused images facilitated image interpretation in common situations of degraded image quality, showed a trend of improved sensitivity in the detection of multivessel disease and generally enhance physicians' confidence in common situations of intermediate lesions. Additionally, the mental allocation of a given artery to its corresponding myocardial segments relies on standard vascular territories definition, which is known to be frequently inaccurate due to patients' anatomy variability, resulting in the erroneous identification of the culprit vessel. Same trends towards improved accuracy were reported by other groups (10, 11).

#### Technical background: image registration

From a technical perspective, MIF employs methodologies from the *image registration field* to spatially align two or more datasets so that anatomical and functional features can be co-localized point-by-point in each dataset or in the newly created fused representation. Two strategies are currently available to perform MIF. In its most general formulation, called *software-based*, MIF works on images acquired at different times and with different devices and is achieved by a sequence of image processing operations that *transform* one image into another by maximizing a mathematically defined index of similarity

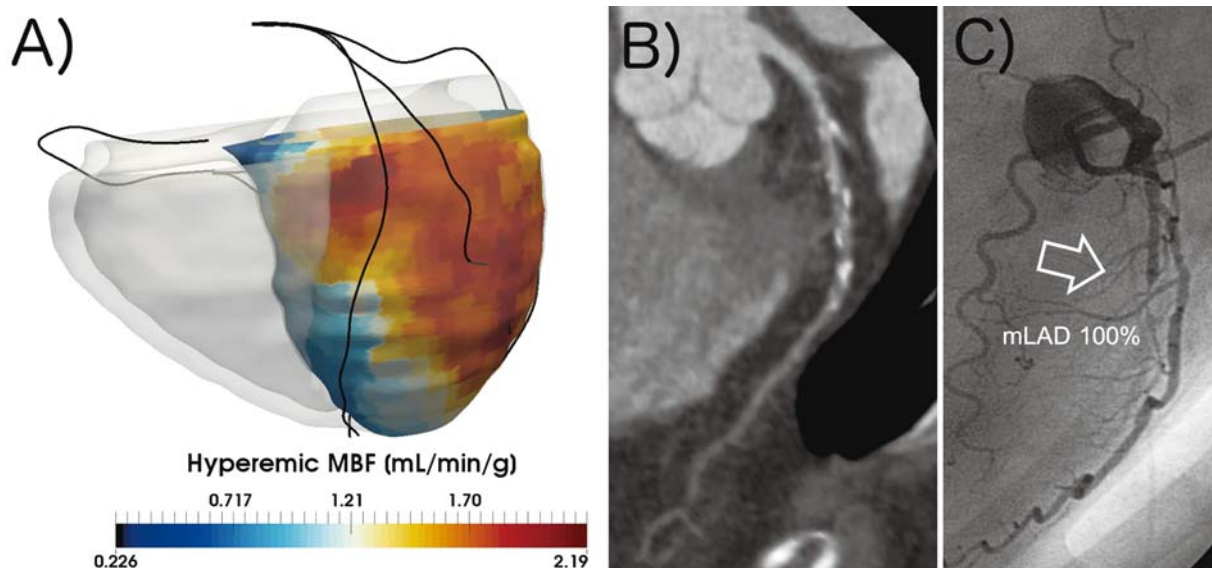
between the two datasets (12, 13). In Figure 1 an example is shown of PET/CTA fusion. In this case, the fusion was obtained by using the left ventricle (LV) extracted from both datasets as the common feature for the initial alignment that is then optimized with mutual information techniques (14) by including the right ventricle (RV). Image registration has become a very active area of research in biomedical image processing with more sophisticated algorithms being constantly introduced. A description of this field is beyond the scope of this manuscript and we refer the readers to specific reviews (12, 13). The second approach is *hardware-based* and allows MIF by means of *hybrid devices*, such as PET/CT, SPECT/CT or PET/MR (15, 16). The patient is sequentially acquired with the two modalities during one imaging session with no registration theoretically needed. In practice, the presence of respiratory and cardiac motion or unexpected body motion often requires the use of software tools to correct for the misalignment and avoid artifacts.

For the scope of the present review, we will primarily focus on CTA as source of anatomy and SPECT/PET as source of physiology, as the fusion of these modalities is the most commonly implemented and tested in CAD assessment.

#### Multimodality image fusion implementations and clinical results

##### Coronary anatomy and myocardial relative perfusion

Fusion techniques for SPECT (PET)/CTA have been available to scientists for almost a decade. Coronary arteries are extracted from the CTA and merged to a map of relative perfusion obtained from the nuclear modalities. Gaemperli and collaborators (10) developed a hybrid display of the CTA-derived coronary and LV epicardium color-coded with the SPECT-derived perfusion map by means of volume-rendering techniques. The technology was validated on a cohort of 180 patients: the fusion display allowed to properly classify about half of the lesions deemed equivocal with a side-by-side



**Fig. 2** A) CTA-derived 3D surface model of the myocardium color-coded with MBF values with patient-specific coronary centerlines, B) CTA images of the LAD, C) angiographic findings for the LAD. mLAD: mid Left Anterior Descending.

reading adding diagnostic power in one third of the analyzed patients. In Rispler et al. (17), the authors used a hybrid SPECT/CT to investigate 56 patients with suspected CAD and demonstrated an increased specificity and positive predictive value compared to stand-alone CTA; they specifically envisioned a role for MIF for subgroups of patients characterized by questionable abnormalities at CTA. In Slomka et al. (18), authors performed automated software-based SPECT/CTA image registration, evaluated its feasibility in clinical settings and used the coronary anatomy to adjust the standard vascular territory classification. This resulted in improved receiver-operating-characteristics (ROC) curves for the LCX and RCA territories. MIF has been an important research area in our laboratory (12) and we recently published a multi-center validation of our 2<sup>nd</sup> generation image fusion technique (14, 19). Pivotal in our approach is the *concept of quantitative fusion* to move beyond a simple *display* of fused images. Our fusion technique relies on precise 3D modeling of the biventricular myocardium, coronaries with lesions location and quantification of perfusion defects. Myocardial mass at risk (MAR) was computed based on the single acquisitions in terms of physiological MAR (MAR<sup>p</sup>), anatomical MAR (MAR<sup>a</sup>) and based on fused representation (MAR<sup>f</sup>). Our study showed a significant increase in diagnostic performance of the MAR<sup>f</sup> compared to stand-alone analysis (19).

Larger studies have also investigated the benefits of MIF with conflicting results. In the EVINCI study (20) a more reliable identification of culprit lesions, vascular territory reclassification and improved diagnostic specificity were evidenced with respect to single modalities; other studies showed that overall diagnostic improvements may be limited

when compared with FFR (21). Surprisingly, in a recent study (22), hybrid imaging did not improve diagnostic accuracy.

Coronary Anatomy and PET-derived Myocardial Blood Flow

In recent years, the use of PET-derived quantification of absolute myocardial blood flow (23) (MBF) as a more reliable noninvasive technology to assess CAD for both initial and advanced stages, and the use of invasive FFR as reference for lesions stratification, resulted in the inclusion of MBF also into MIF approaches. From a technical perspective, the image registration is likely to use the same methodologies, but the incorporation of MBF is expected to add diagnostic value to the integration compared to the use of relative perfusion, specifically in cases of balanced ischemia and triple-vessel disease. Two recent studies (24, 25) tested hybrid imaging of <sup>15</sup>O-water PET/CTA against angiographic findings and invasive FFR. In both cases the investigators showed that MIF can greatly reduce occurrences of false-positives. In Figure 2 a case analyzed with MIF in our lab is depicted as an example of quantitative fusion with MBF: a parametric map of MBF is displayed on the 3D reconstruction of myocardium and coronary centerlines; the decrease in hyperemic MBF in the LAD territory is correlated to CTA images and angiographic findings.

Finally, while PET-derived MBF quantification cannot distinguish between epicardial and microvascular disease, the fused approach and particularly the excellent negative predictive value of CTA can help physicians to exclude focal disease consequently diagnosing microvascular dysfunction and avoiding unnecessary catheterization (23).

**Limitations of multimodality image fusion strategy**

Despite the encouraging findings of pilot studies as well as larger investigations, MIF has not entered clinical practice. A number of technological and clinical challenges has limited its routine application so far. One of the main technological barrier deals with the anatomy retrieval, necessary for some MIF implementations. While quantification of nuclear perfusion studies is highly computerized, the detailed segmentation of CTA images (coronary trees and myocardium) has not reached the same level of automation and may require time-consuming manual interactions, considerably diminishing MIF feasibility. Mindful of the importance of this step, our team has greatly worked on the development of automated and time-efficient techniques for the segmentation of cardiac CT with promising results (26), the aim being the creation of fully-automated algorithms for the extraction of relevant information from both image datasets and their ultimate fusion within minutes and with limited user interaction.

Currently software packages for MIF exist in the form of research applications rather than fully developed and validated modules. An additional effort is required to streamline the process from the individual acquisitions, which according to the most general framework are obtained from different devices, to the final fused display readily available to the physician. A comprehensive validation of our image segmentation and registration techniques is presently being performed in our lab on a database of CTA/SPECT datasets acquired at different medical centers.

From the clinical perspective, a common criticism to MIF relies on its need for two imaging sessions. It is worth mentioning that the rationale behind the use of MIF as a diagnostic strategy is not that all patients with suspected CAD should undergo both imaging acquisitions, but rather that by means of MIF and in the context of a sequential imaging approach (i.e. a second test being ordered when the first is equivocal) physicians could fully benefit from the synergistic power of fused anatomy and function.

Another important limitation associated with the MIF strategy is the radiation dose delivered to the patient (27). A continuous effort is being supported to decrease radiation burden for all modalities, particularly for nuclear acquisitions. A case can be made for PET studies whose 2-4 mSv radiation dose range is significantly lower than in SPECT, in addition to PET's ability to compute MBF. Even when accompanied by a CTA (radiation dose 0.5-3 mSv) the global radiation burden remains below the one that would be delivered during a catheterization session, favoring a dual-modality strategy to avoid unnecessary invasive procedures.

**Conclusions**

Multimodality image fusion represents a valid and beneficial diagnostic strategy for CAD assessment, particularly for subgroups of patients with abnormal findings at the initial test. The recent introduction of PET-derived MBF quantification into clinical practice has further enhanced the diagnostic power of the fusion approach and recognized it as a potential noninvasive mean to identify microvascular disease.

**Acknowledgments**

None.

**Sources of funding**

The research reported in this work was in part funded by the US National Institutes of Health: grant number R01 HL143350 (PI: EV Garcia).

**Conflicts of interest**

None declared.

---

Reprint requests and correspondence:

Marina Piccinelli, PhD

Department of Radiology and Imaging Sciences, Emory University School of Medicine, 1364 Clifton Rd, NE, Atlanta, Georgia, 30322, USA

E-mail: mpiccin@emory.edu

---

## References

1. Benjamin EJ, Virani SS, Callaway CW, et al. Heart disease and stroke statistics-2018 Update: A report from the American Heart Association. *Circulation* 2018; 137: e67-e492.
2. Patel MR, Peterson ED, Dai D, et al. Low diagnostic yield of elective coronary angiography. *N Engl J Med* 2010; 362: 886-95.
3. Patel MR, Dai D, Hernandez AF, et al. Prevalence and predictors of nonobstructive artery disease identified with coronary angiography in contemporary clinical practice. *Am Heart J* 2014; 167: 846-52. e2.
4. Achenbach S, Friedrich MG, Nagel E, et al. CV imaging: what was new in 2012? *JACC Cardiovasc Imaging* 2013; 6: 714-34.
5. Gould KL. Does coronary flow trump coronary anatomy? *JACC Cardiovasc Imaging* 2009; 2: 1009-23.
6. Bishop AH, Samady H. Fractional flow reserve: critical review of an important physiologic adjunct to angiography. *Am Heart J* 2004; 147: 792-802.
7. Tonino PA, Fearon WF, De Bruyne B, et al. Angiographic versus functional severity of coronary artery stenoses in the FAME study fractional flow reserve versus angiography in multivessel evaluation. *J Am Coll Cardiol* 2010; 55: 2816-21.
8. Blankstein R, Di Carli MF. Integration of coronary anatomy and myocardial perfusion imaging. *Nat Rev Cardiol* 2010; 7: 226-36.
9. Santana CA, Garcia EV, Faber TL, et al. Diagnostic



- performance of fusion of myocardial perfusion imaging (MPI) and computed tomography coronary angiography. *J Nucl Cardiol* 2009; 16: 201-11.
10. Gaemperli O, Schepis T, Valenta I, et al. Cardiac image fusion from stand-alone SPECT and CT: clinical experience. *J Nucl Med* 2007; 48: 696-703.
  11. Prior JO, Farhad H, Muller O. Multimodality imaging in ischemic cardiomyopathy. *Curr Cardiovasc Imaging Rep* 2014; 7: 9285.
  12. Piccinelli M, Garcia E. Multimodality image fusion for diagnosing coronary artery disease. *J Biomed Res* 2013; 27: 439-51.
  13. Slomka PJ, Baum RP. Multimodality image registration with software: state-of-the-art. *Eur J Nucl Med Mol Imaging* 2009; 36: S44-S55.
  14. Faber TL, Santana CA, Piccinelli M, et al. Automatic alignment of myocardial perfusion images with contrast-enhanced cardiac computed tomography. *IEEE Trans Nucl Sci* 2011; 58: 2296-302.
  15. Giannopoulos AA, Gaemperli O. Hybrid imaging in ischemic heart disease. *Rev Esp Cardiol (Engl Ed)* 2018; 71: 382-90.
  16. Gaemperli O, Kaufmann PA, Alkadhi A. Cardiac hybrid imaging. *Eur J Nucl Med Mol Imaging* 2014; 41: S91-S103.
  17. Rispler S, Keidar Z, Ghersin E, et al. Integrated single-photon mission computed tomography and computed tomography coronary angiography for the assessment of hemodynamically significant coronary artery lesions. *J Am Coll Cardiol* 2007; 49: 1059-67.
  18. Slomka PJ, Cheng VY, Dey D, et al. Quantitative analysis of myocardial perfusion SPECT anatomically guided by coregistered 64-slice coronary CT angiography. *J Nucl Med* 2009; 50: 1621-30.
  19. Piccinelli M, Santana C, Sirineni GKR, et al. Diagnostic performance of the quantification of myocardium at risk from MPI SPECT/CTA 2G fusion for detecting obstructive coronary disease: A multicenter trial. *J Nucl Cardiol* 2017; doi: 10.1007/s12350-017-0819-x. [Epub ahead of print]
  20. Liga R, Vontobel J, Rovai D, et al. Multicenter multi-device hybrid imaging study of coronary artery disease: results from the Evaluation of INtegrated Cardiac Imaging for the Detection and Characterization of Ischaemic Heart Disease (EVINCI) hybrid imaging population. *Eur Heart J Cardiovasc Imaging* 2016; 17: 951-60.
  21. Rizvi A, Han D, Danad I, et al. Diagnostic performance of hybrid cardiac imaging methods for assessment of obstructive coronary artery disease compared with stand-alone coronary computed tomography angiography: a meta-analysis. *JACC Cardiovasc Imaging* 2018; 11: 589-99.
  22. Danad I, Raijmakers PG, Driessen RS, et al. Comparison of coronary CT angiography, SPECT, PET and hybrid imaging for diagnosis of ischemic heart disease determined by fractional flow reserve. *JAMA Cardiol* 2017; 2: 1100-7.
  23. Schindler TH. Myocardial blood flow: Putting it into clinical perspective. *J Nucl Cardiol* 2016; 23: 1056-71.
  24. Kajander S, Joutsiniemi E, Saraste M, et al. Cardiac positron emission tomography/Computed tomography imaging accurately detects anatomically and functionally significant coronary artery disease. *Circulation* 2010; 122: 603-13.
  25. Danad I, Raijmakers PG, Appelman YE, et al. Hybrid imaging using quantitative H215O PET and CT-based coronary angiography for the detection of coronary artery disease. *J Nucl Med* 2013; 54: 55-63.
  26. Piccinelli M, Faber TL, Arepalli CD, et al. Automatic detection of left and right ventricles from CTA enables efficient alignment of anatomy with myocardial perfusion data. *J Nucl Cardiol* 2014; 21: 96-108.
  27. Flotats A, Knuuti J, Gutberlet M, et al. Hybrid cardiac imaging: SPECT/CT and PET/CT. A joint position statement by the European Association of Nuclear Medicine (EANM), the European Society of Cardiac Radiology (ESCR) and the European Council of Nuclear Cardiology (ECNC). *Eur J Nucl Med Mol Imaging* 2011; 38: 201-12.